

# MénisCare Project

Photo acoustic imaging for measurement  
of meniscus vascularization density

Olivier Jacquin, Eric Lacot, Paolo Paris

27 / 01 / 2023



# Plan

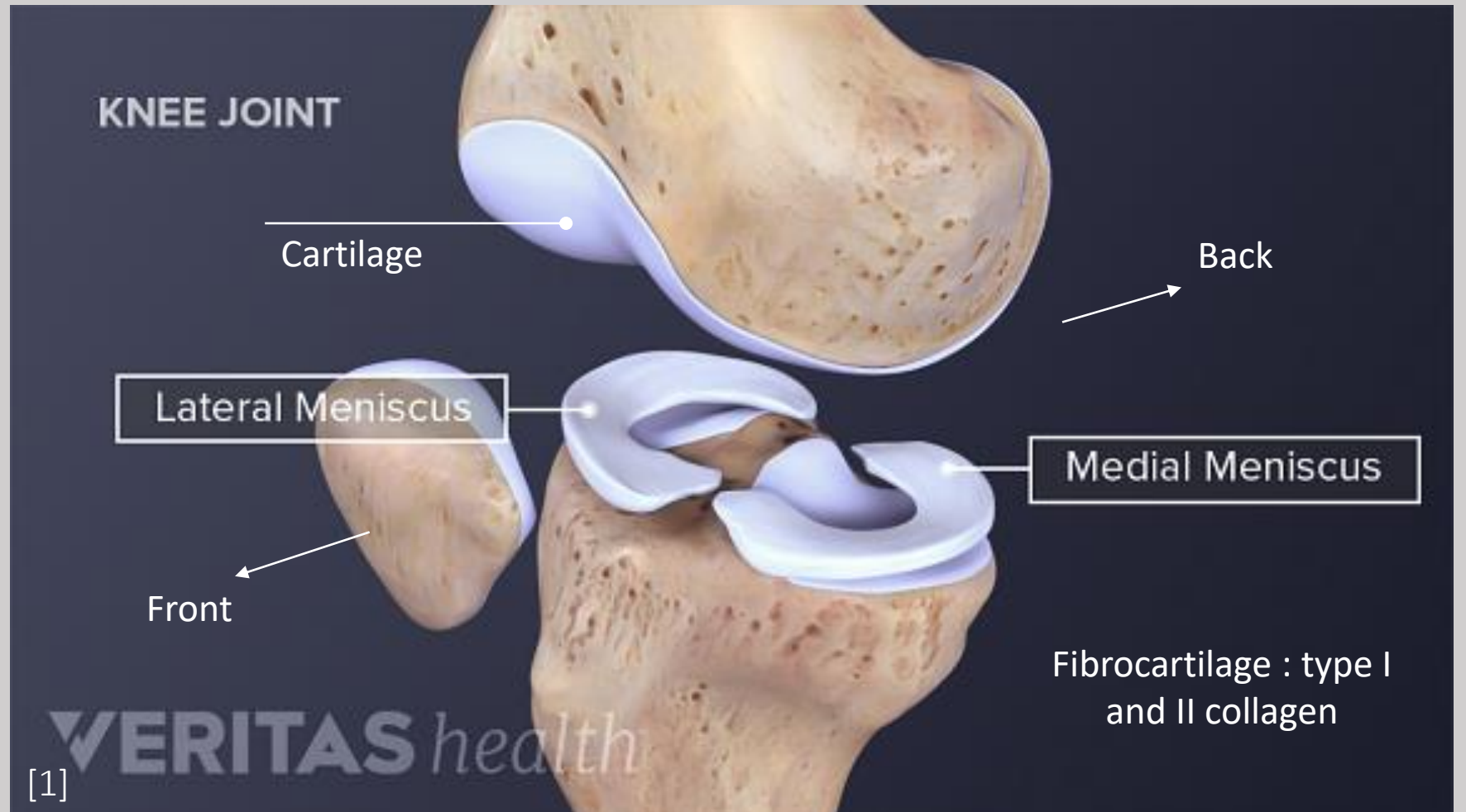
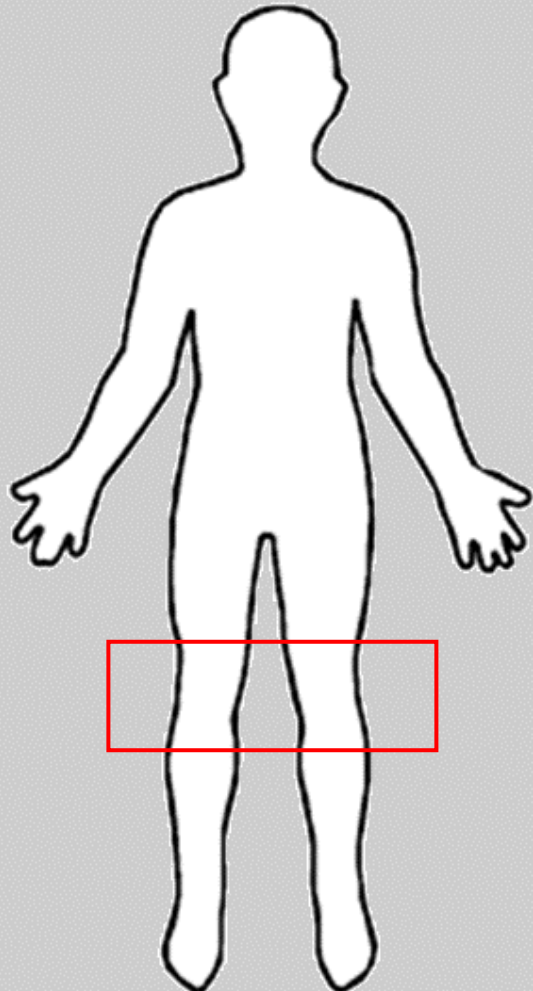
I. The MénisCare project

II. Photo acoustic imaging

III. Results and comparisons


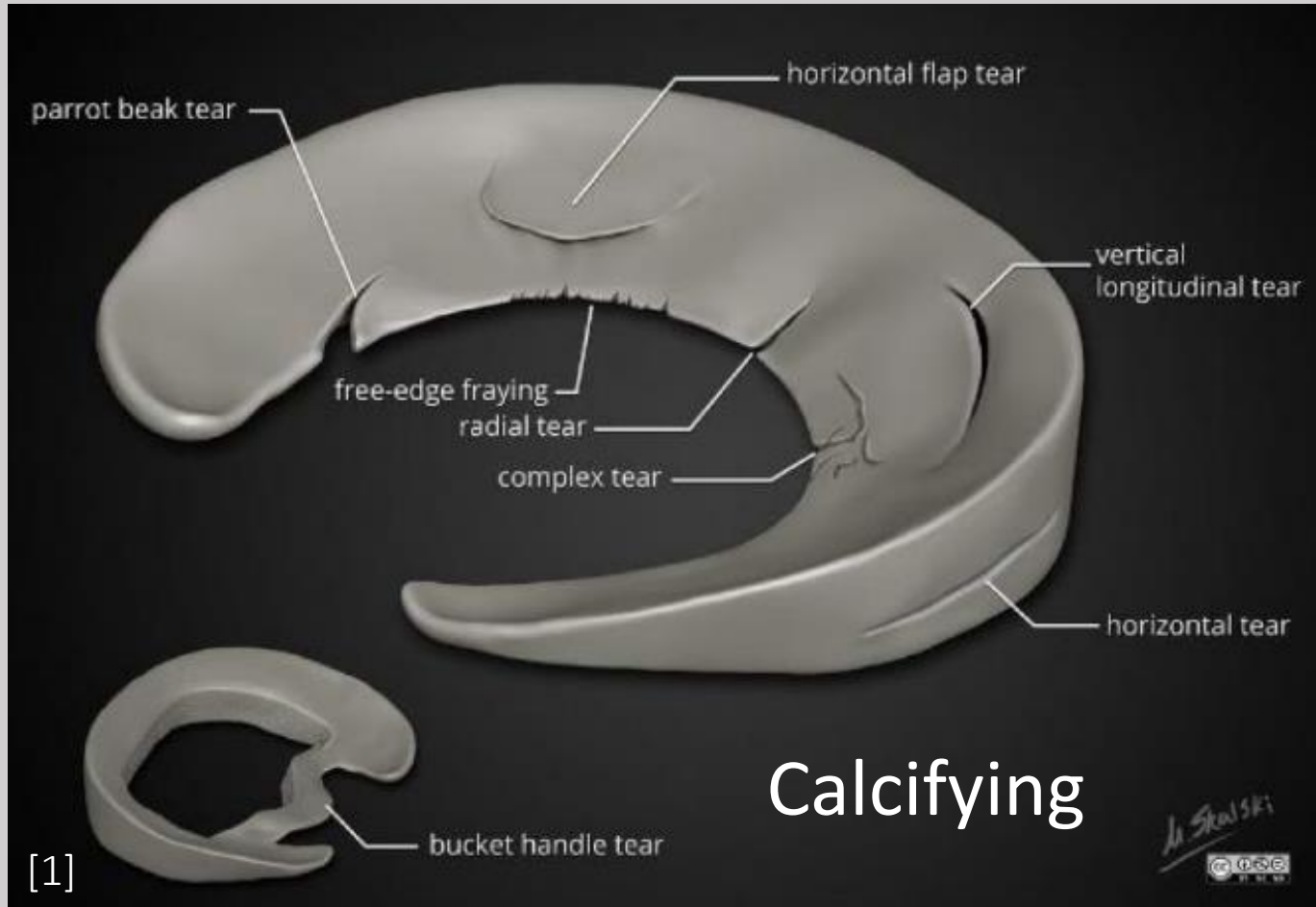
# The MénisCare project

## The meniscus

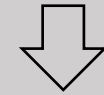


# The MénisCare project

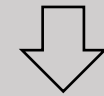
## Damages to the meniscus



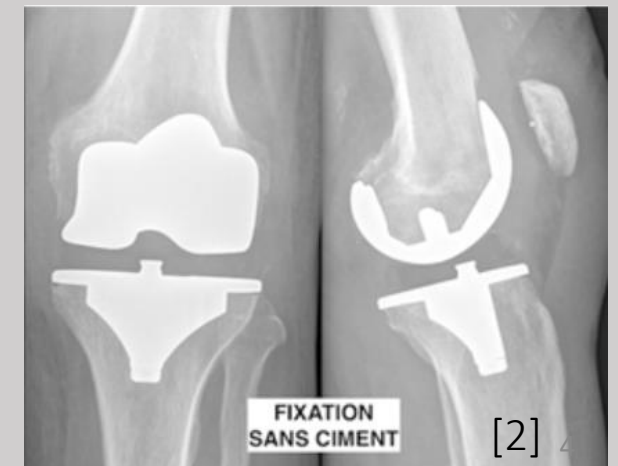
Meniscus suture



Meniscectomy

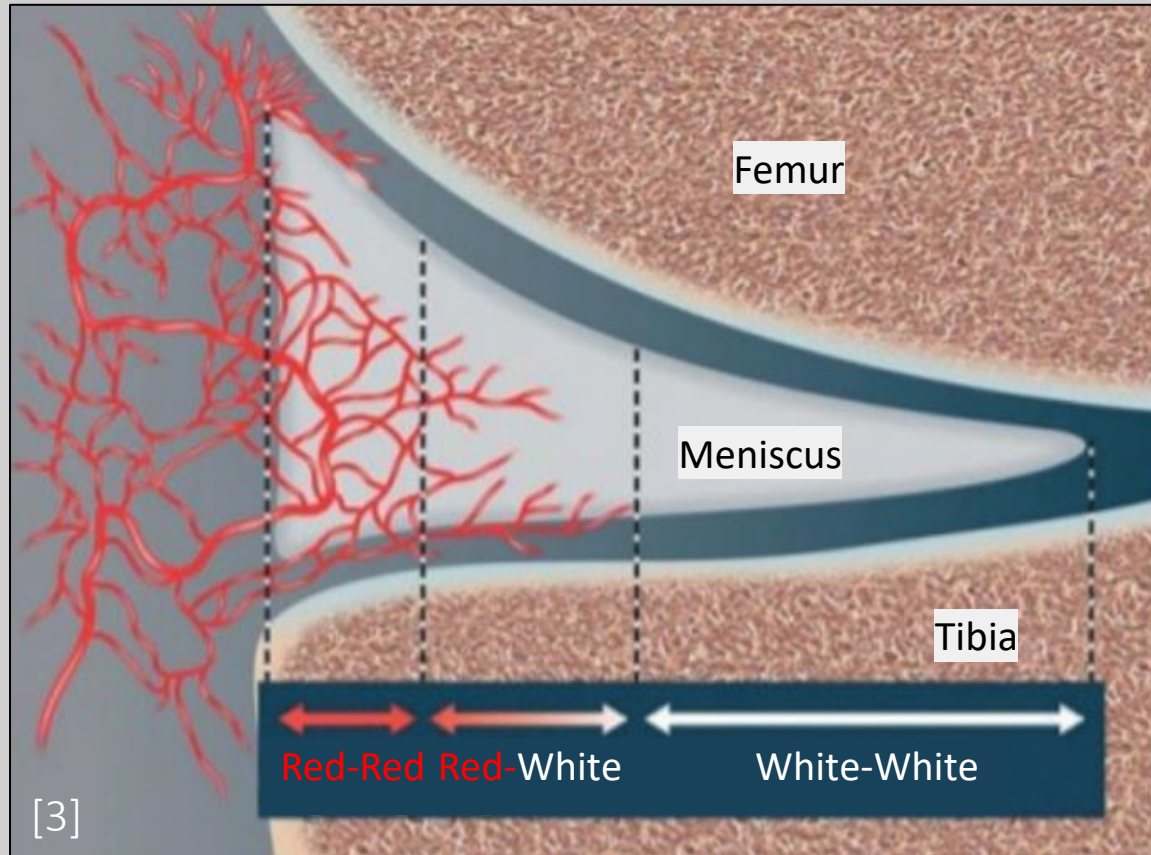


Prosthesis

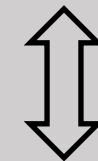

# The MénisCare project

## Meniscectomy or meniscus suture ?



**Vascularisation  
density**



**Objective**

**Photo acoustic  
imaging**

# The MénisCare project

## Proof-of-concept: measuring blood inside meniscus with photo acoustic imaging



Human meniscus extraction

Lateral meniscus

Lateral meniscus



Photo acoustics and MRI

Histological slices



Ex-vivo

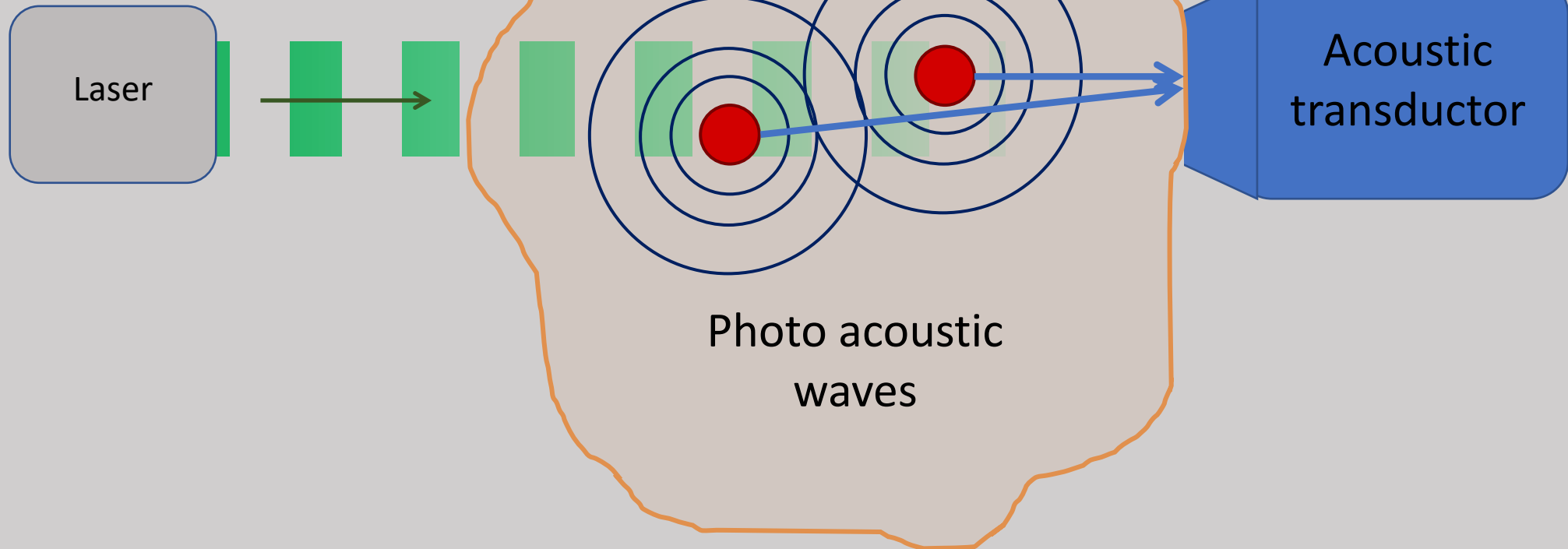
Comparison

Gold standard <sub>6</sub>

# Photo acoustic imaging

## Photo acoustic effect

Time modulated  
laser beam





# Photo acoustic imaging

Photo acoustic

Ultrasound signal



Imaged object




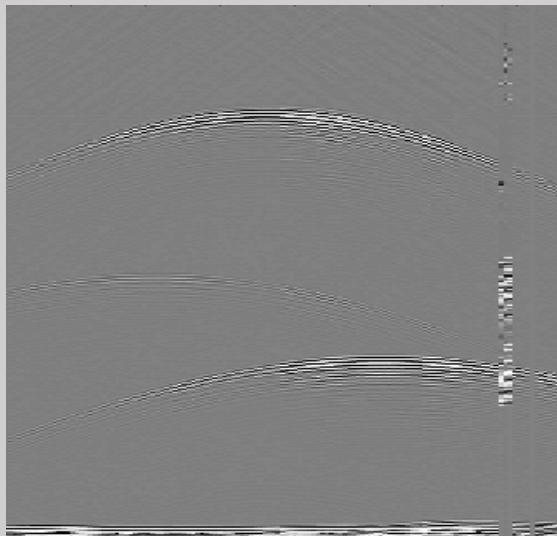


Image reconstruite



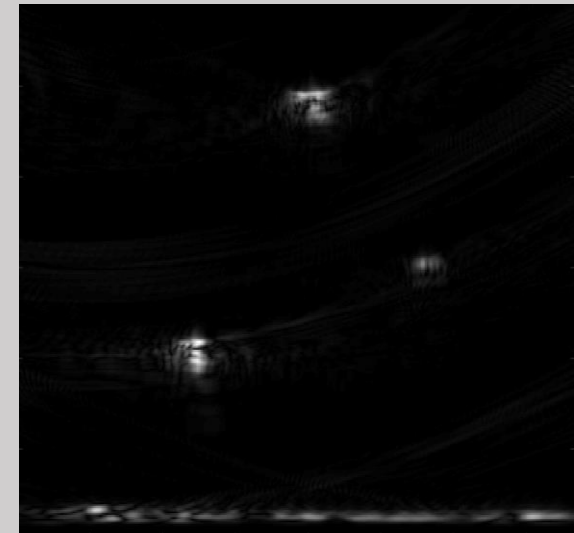
Echography



Back propagation  
reconstruction

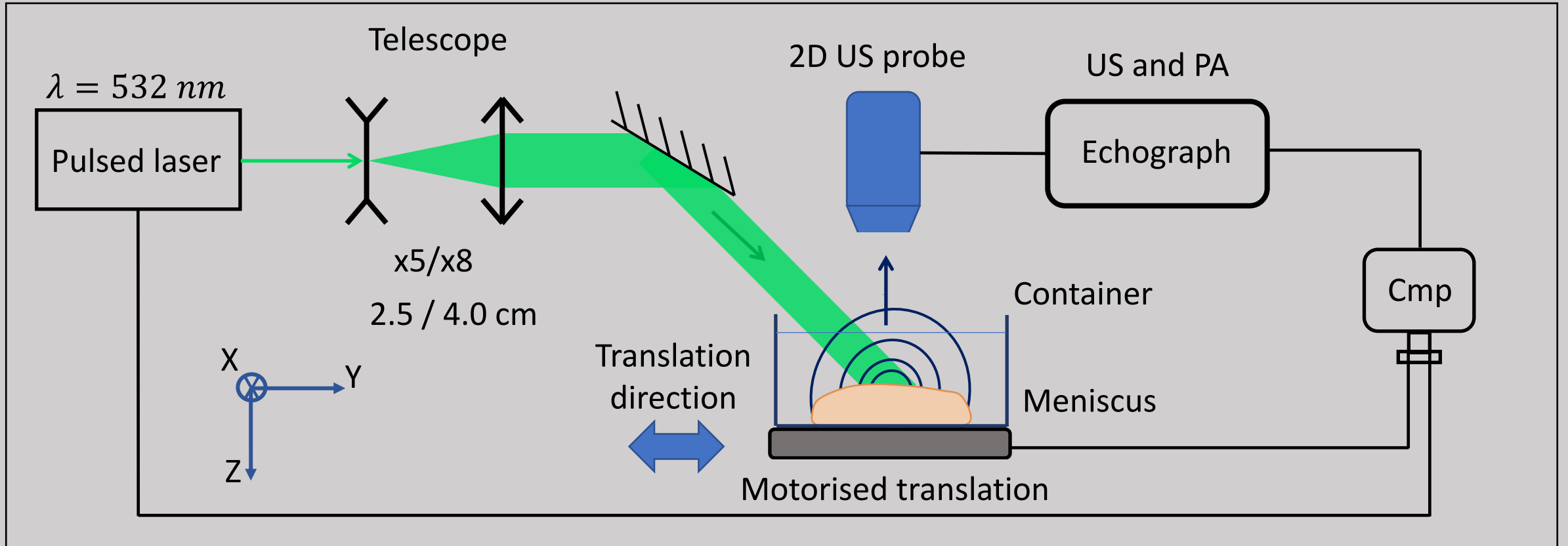
$$\Delta p(\vec{r}, t) - \frac{1}{v_s^2} \frac{\partial^2 p(\vec{r}, t)}{\partial t^2} = 0$$

Reversible






# Experimental set up



# Experimental set up



# Experimental set up Specifications

## Pulsed laser

$$\lambda = 532 \text{ nm}$$

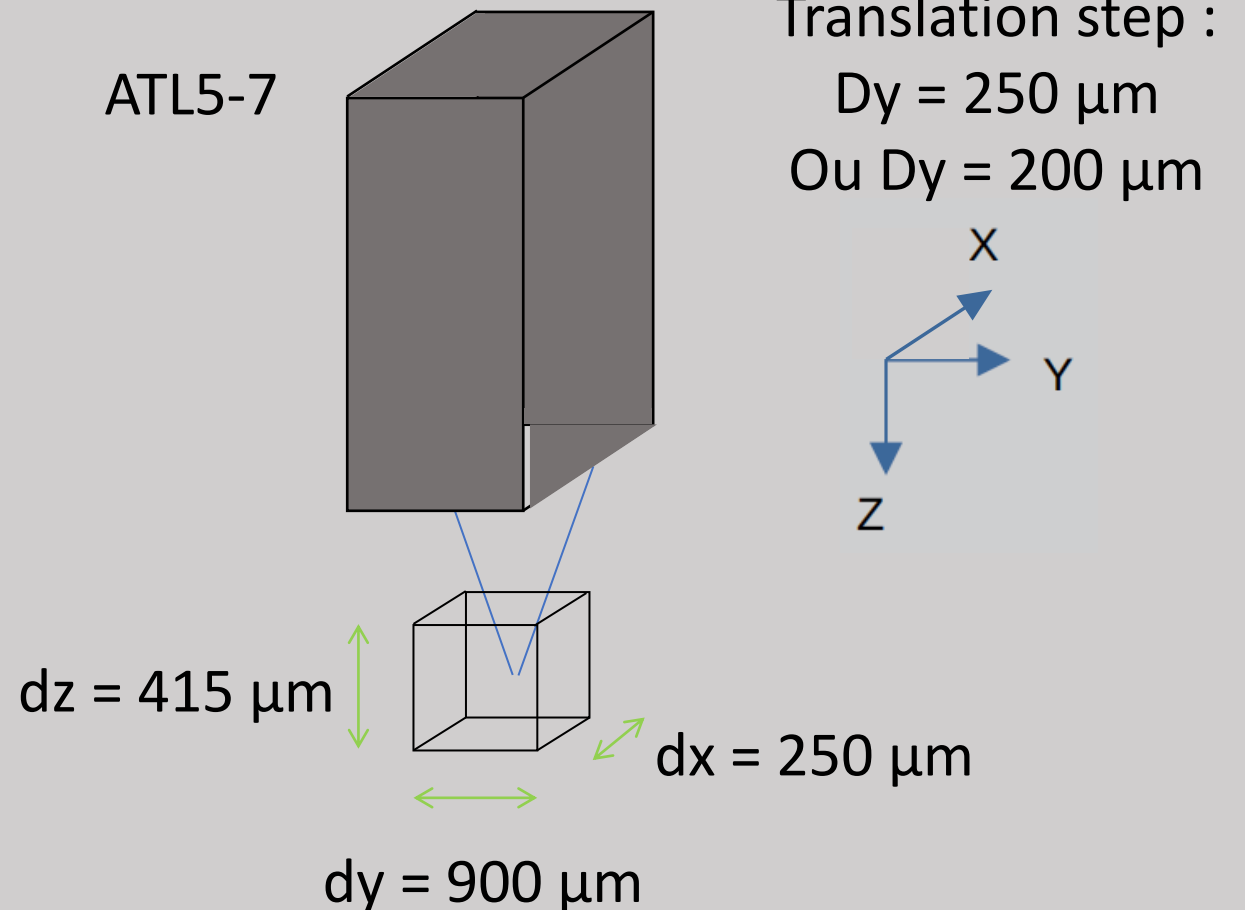
$$F = 10 \text{ Hz}$$

$$\Delta t = 6 \text{ ns}$$

$$\rho = 5 \text{ mJ} \cdot \text{cm}^{-2} (\phi = 4.0 \text{ cm})$$

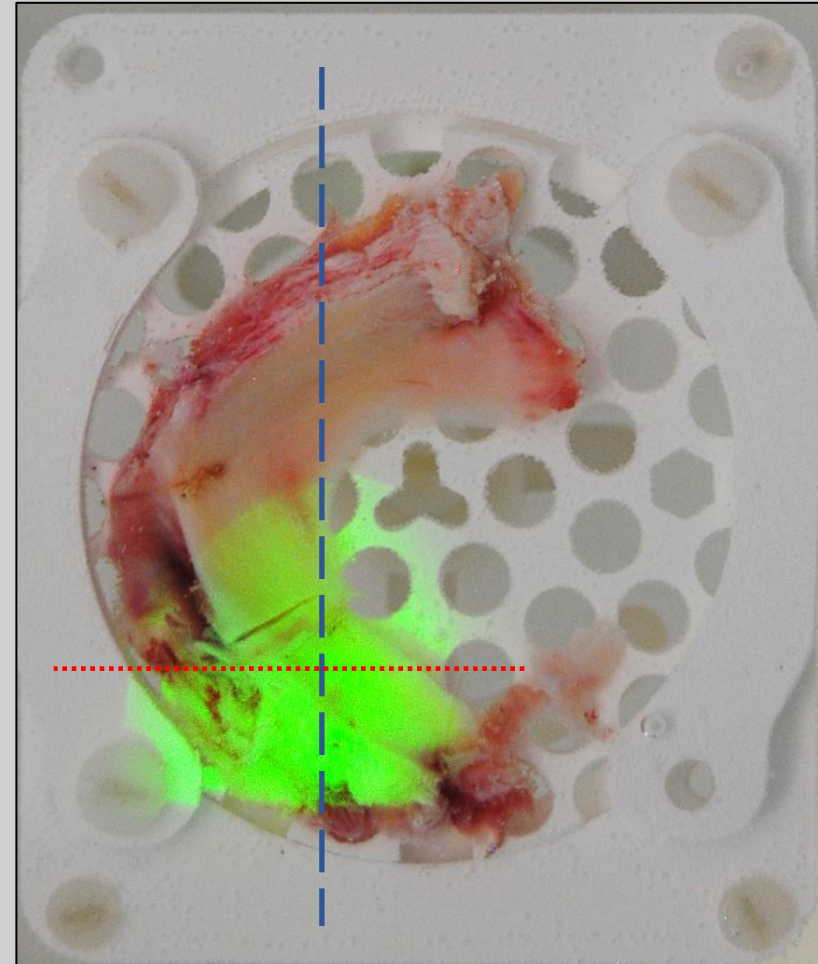
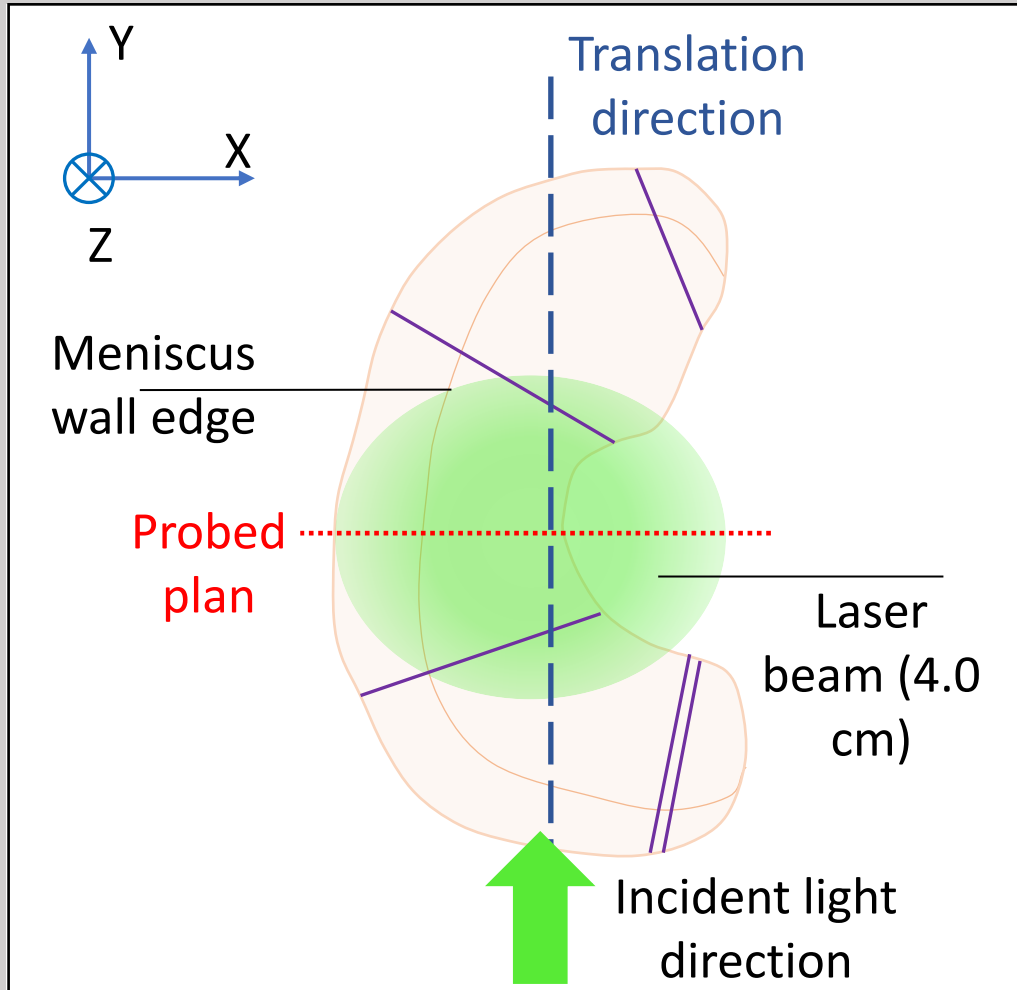
$$\rho = 20 \text{ mJ} \cdot \text{cm}^{-2} (\phi = 2.5 \text{ cm})$$

## US probe



# Results and comparison

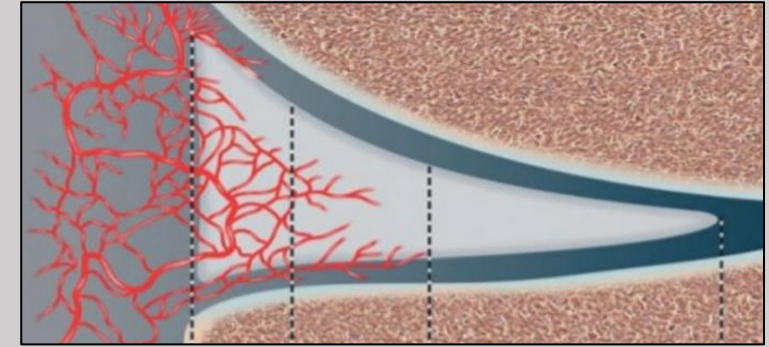
## Orientation A



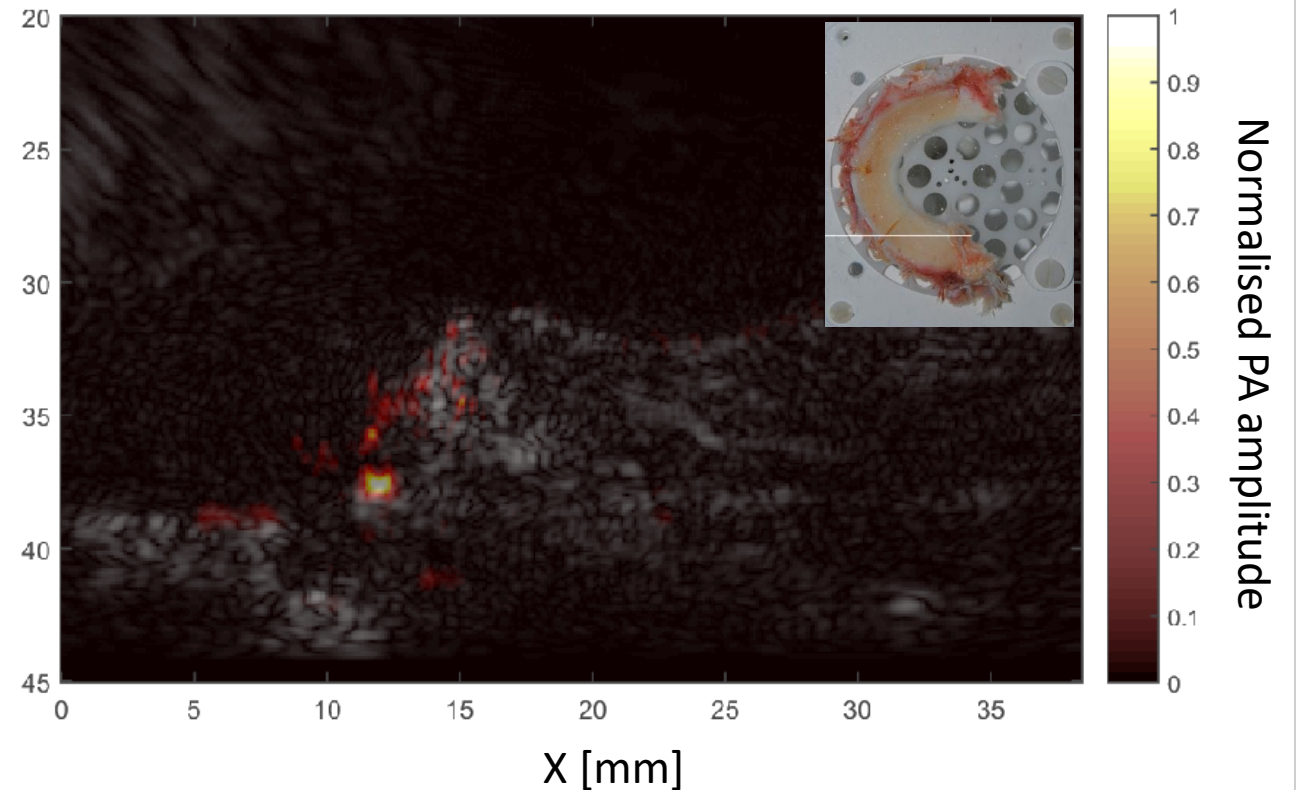
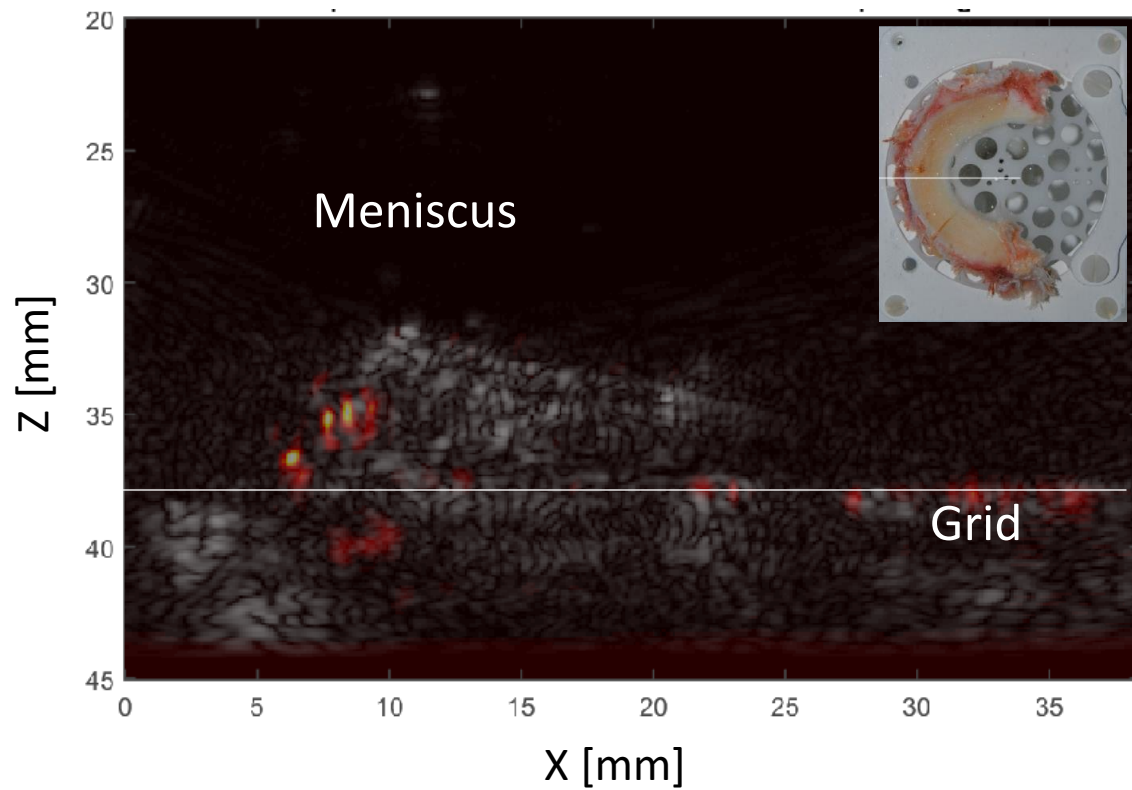
Results and comparison  
Meniscus n°7

Video

# Results and comparison Meniscus n°7

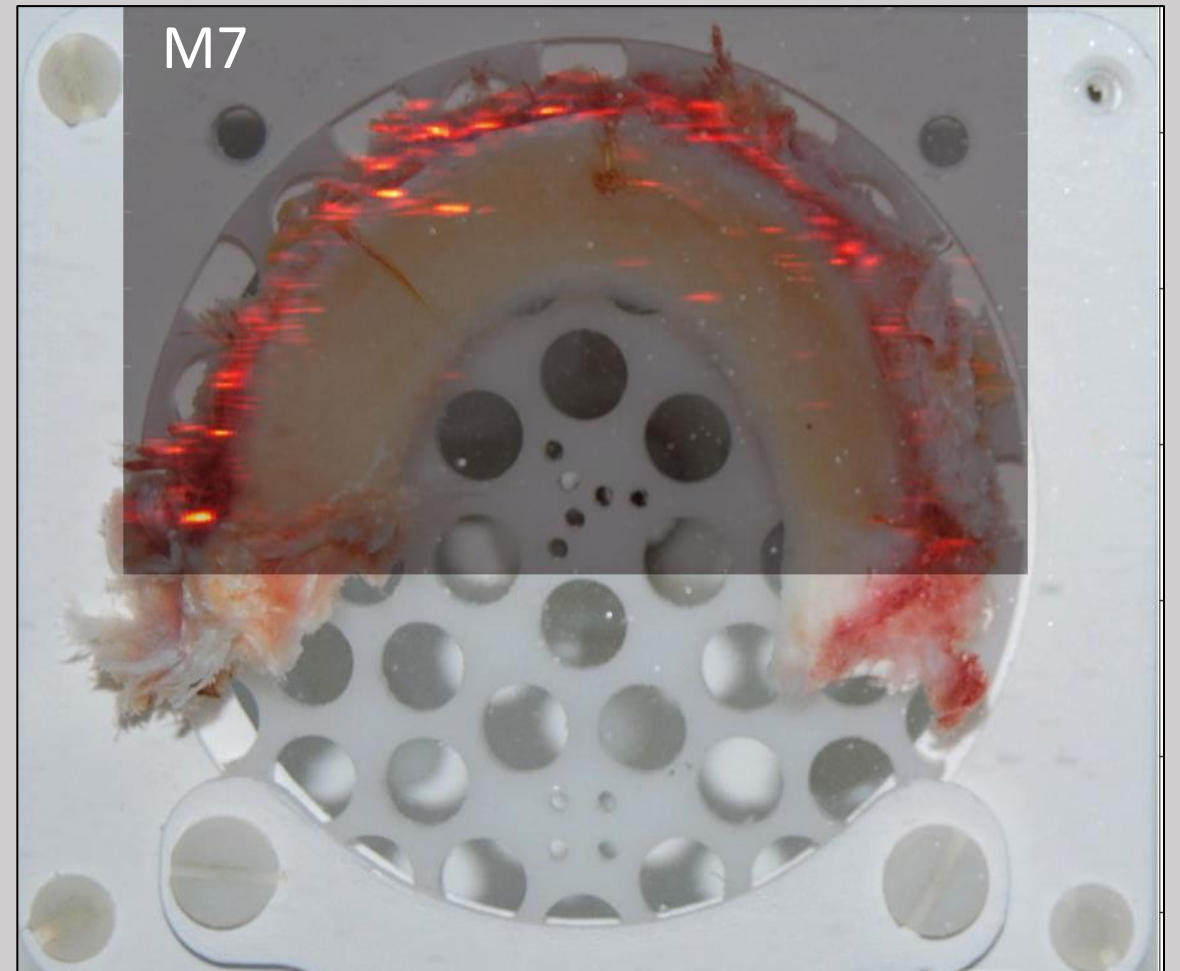
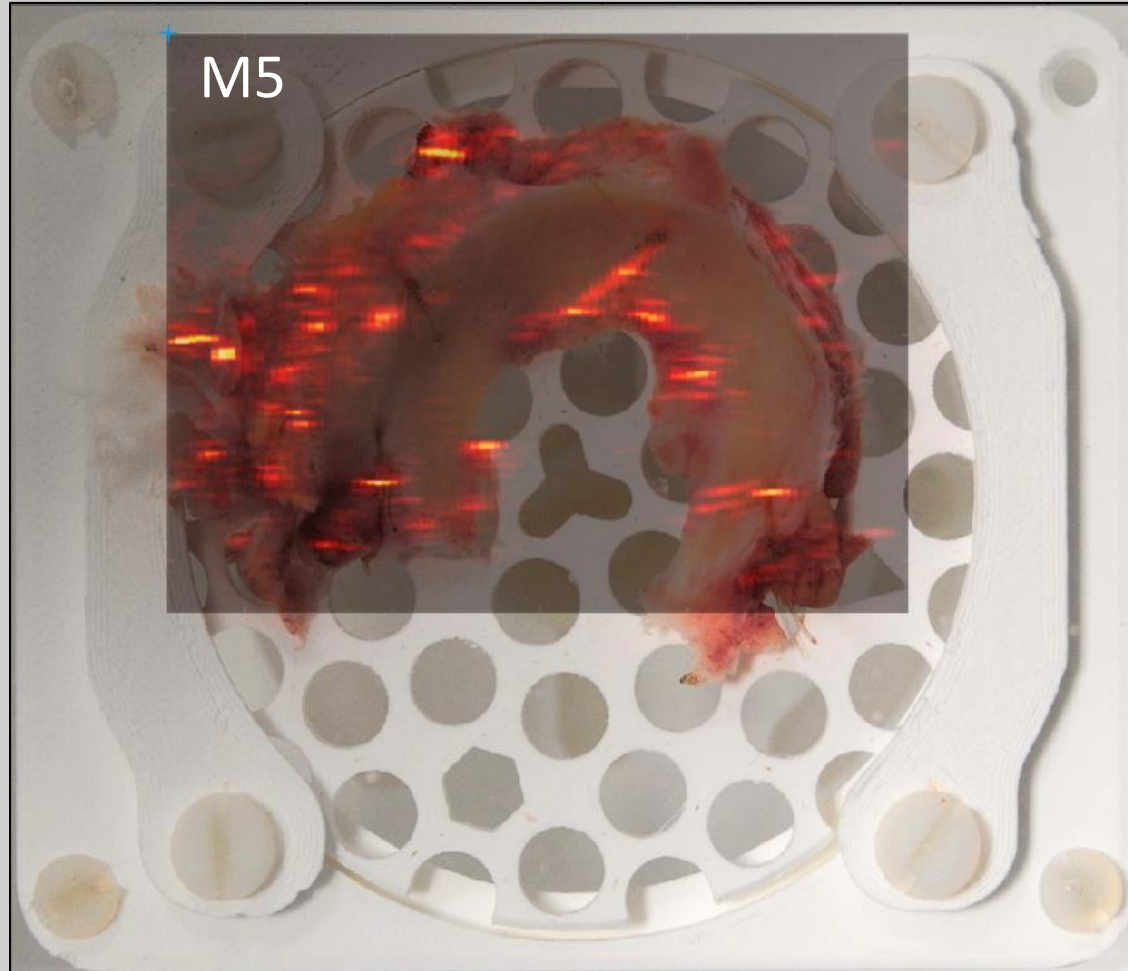


Red: PA    Gray: US



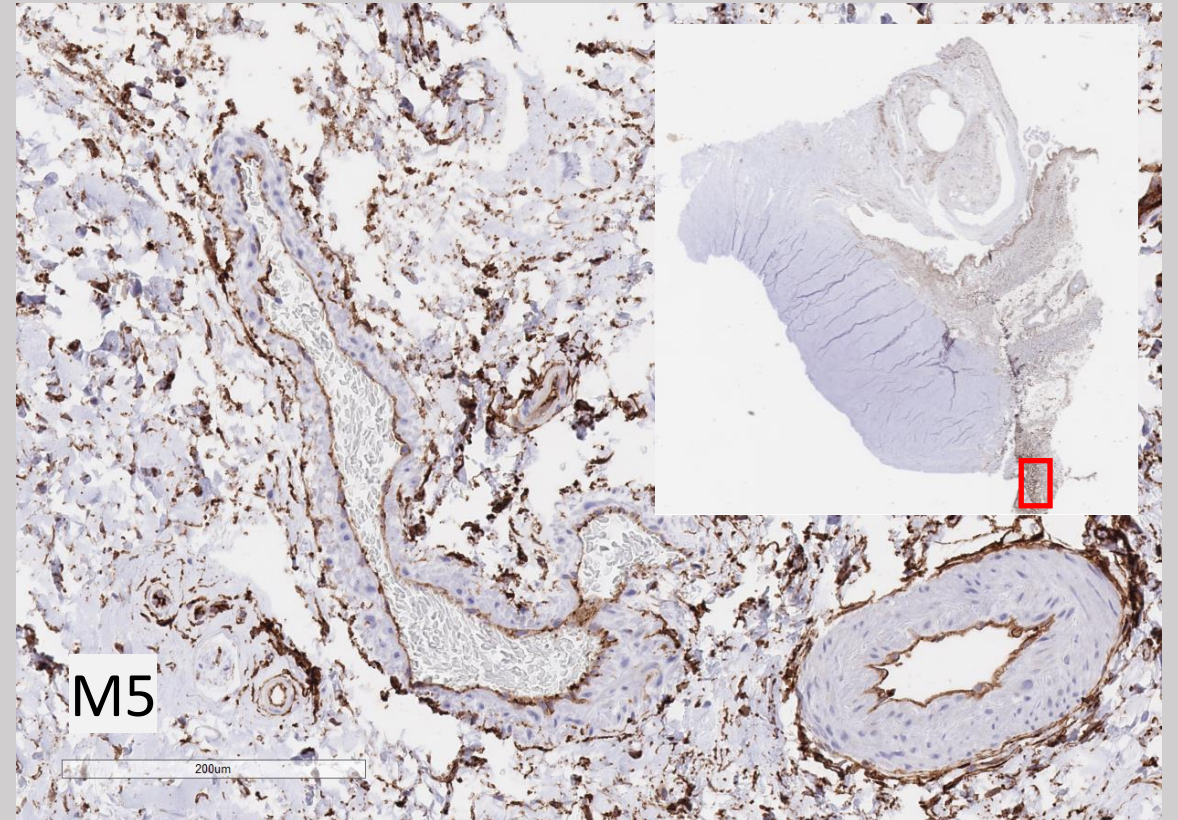
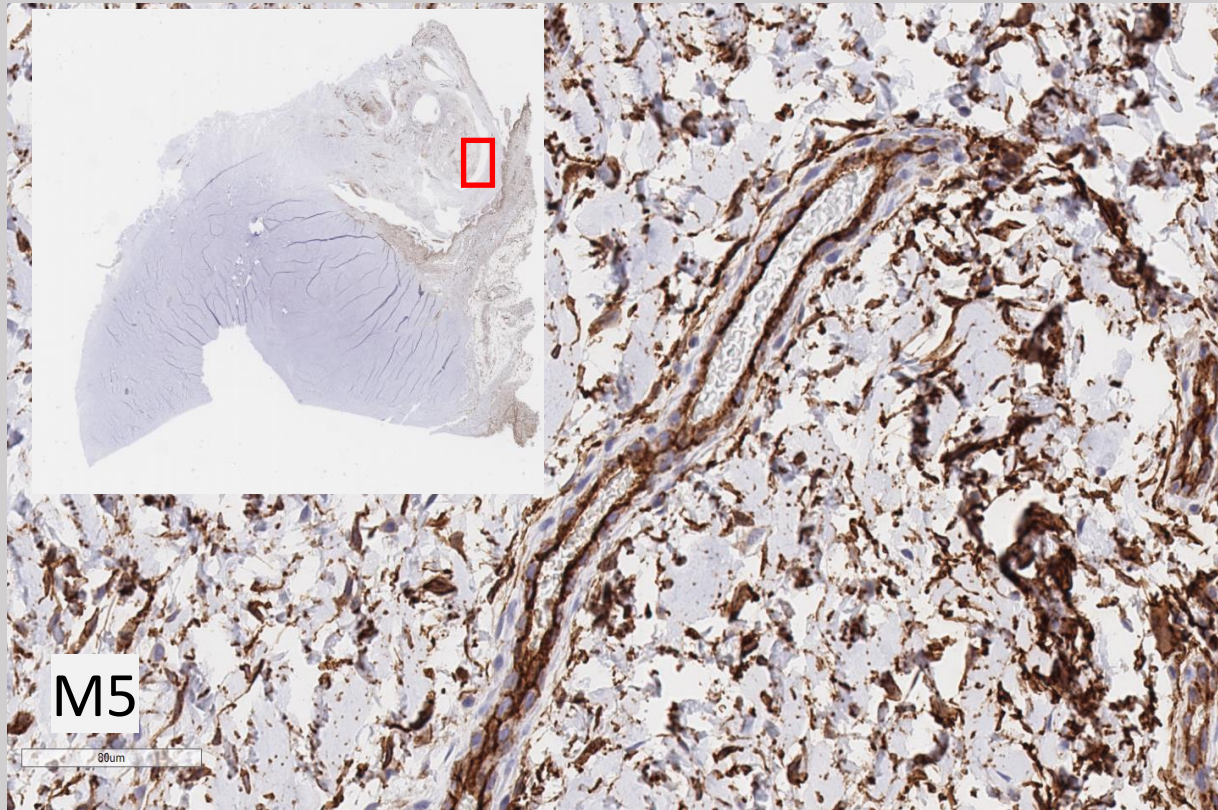


# Results and comparison Menisci n°5 and 7





# Results and comparison



Results and comparison  
Conclusion

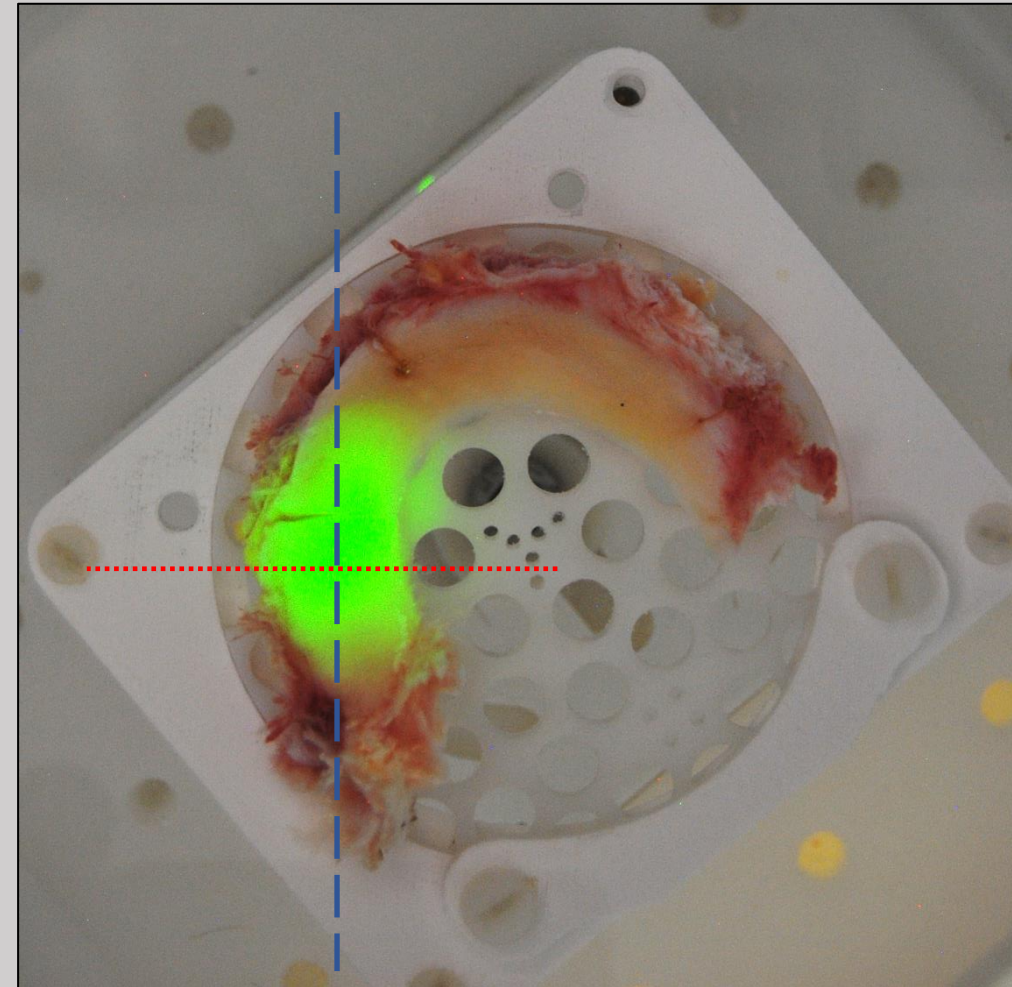
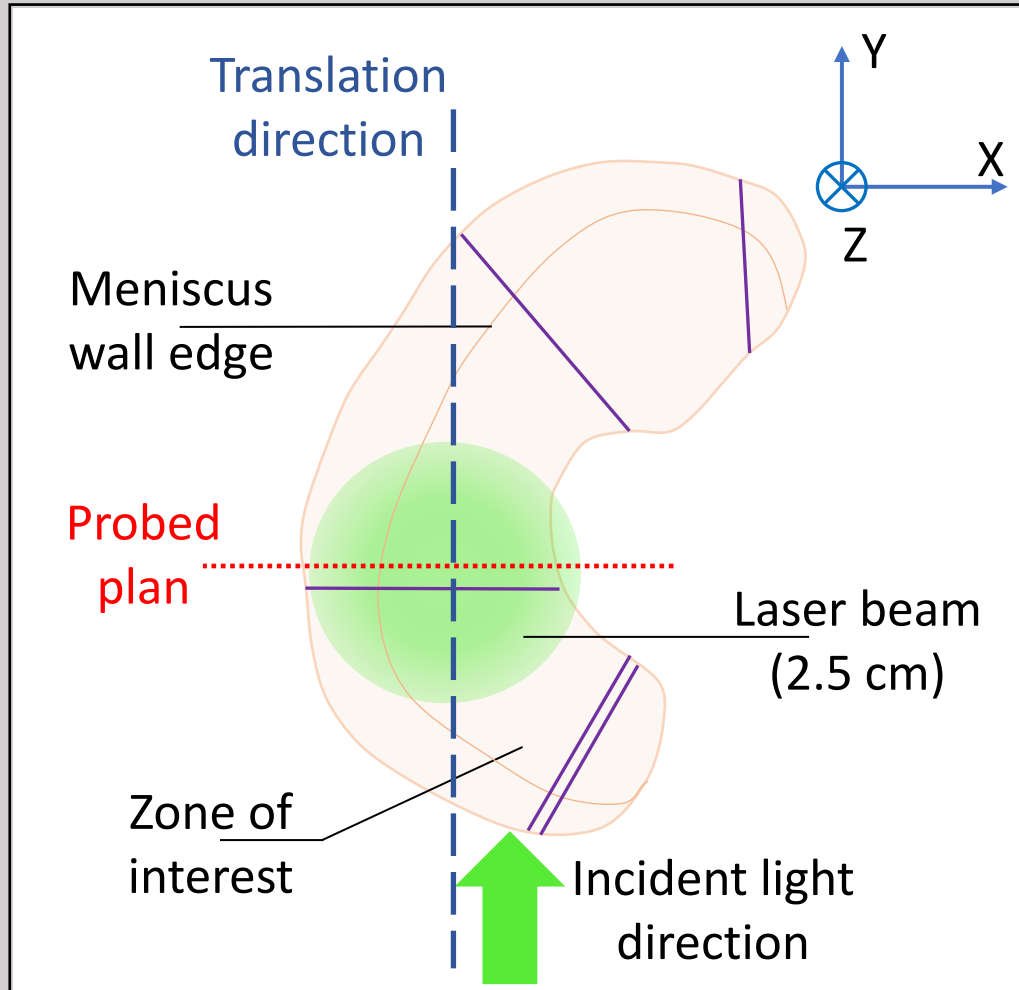
**PA measurements in agreement with medical papers**

**Blood measured in menisci**



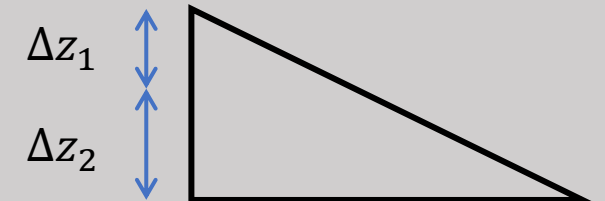
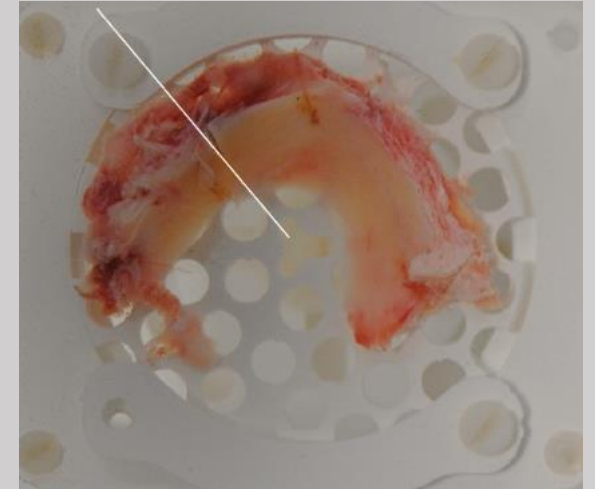
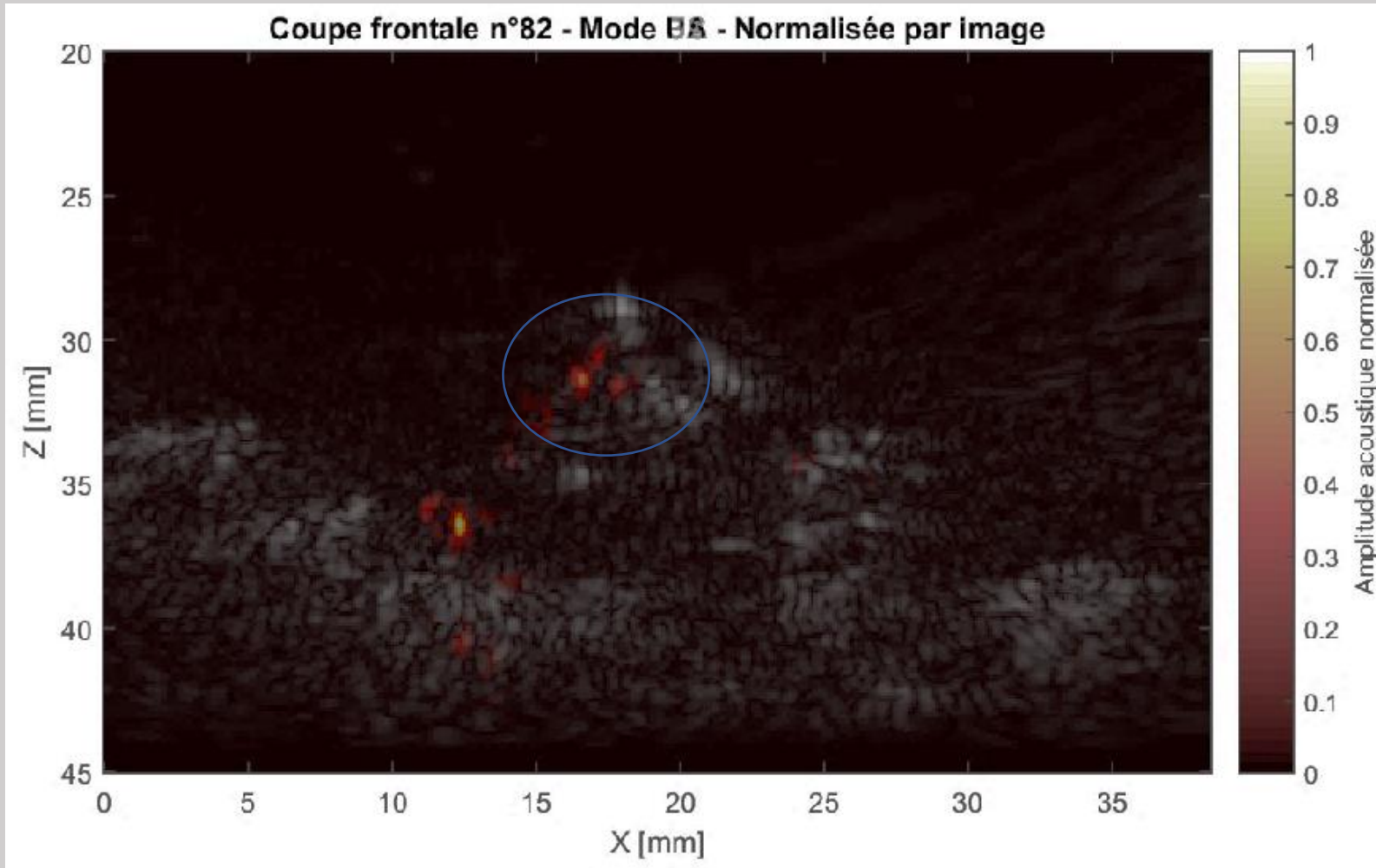
# Results and comparison

## Zone of interest



# Results and comparison

## Meniscus n° 6 - PA

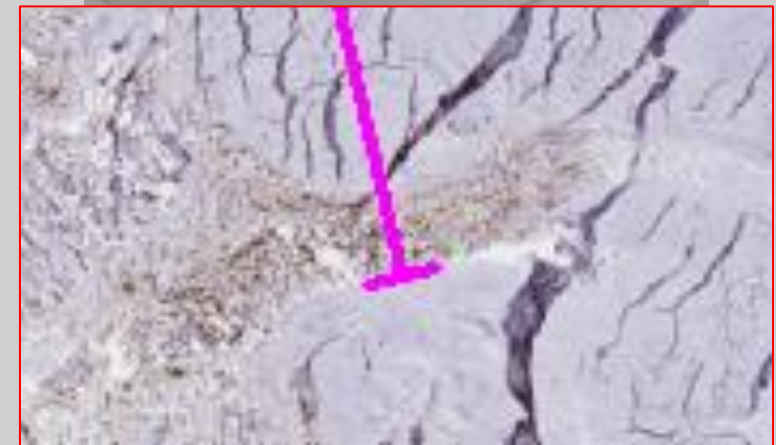
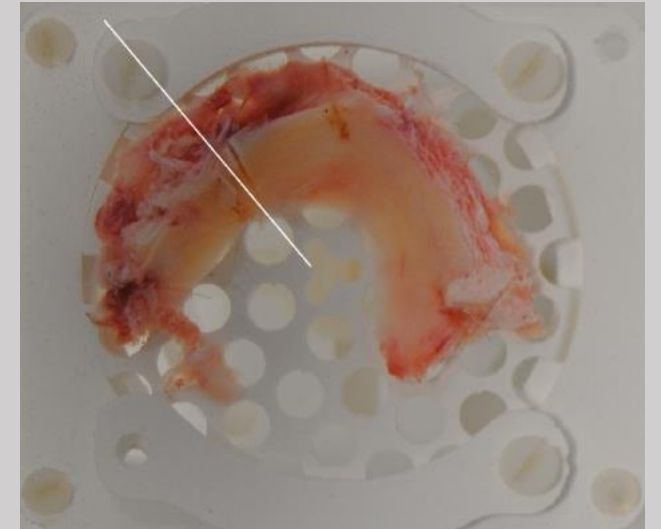
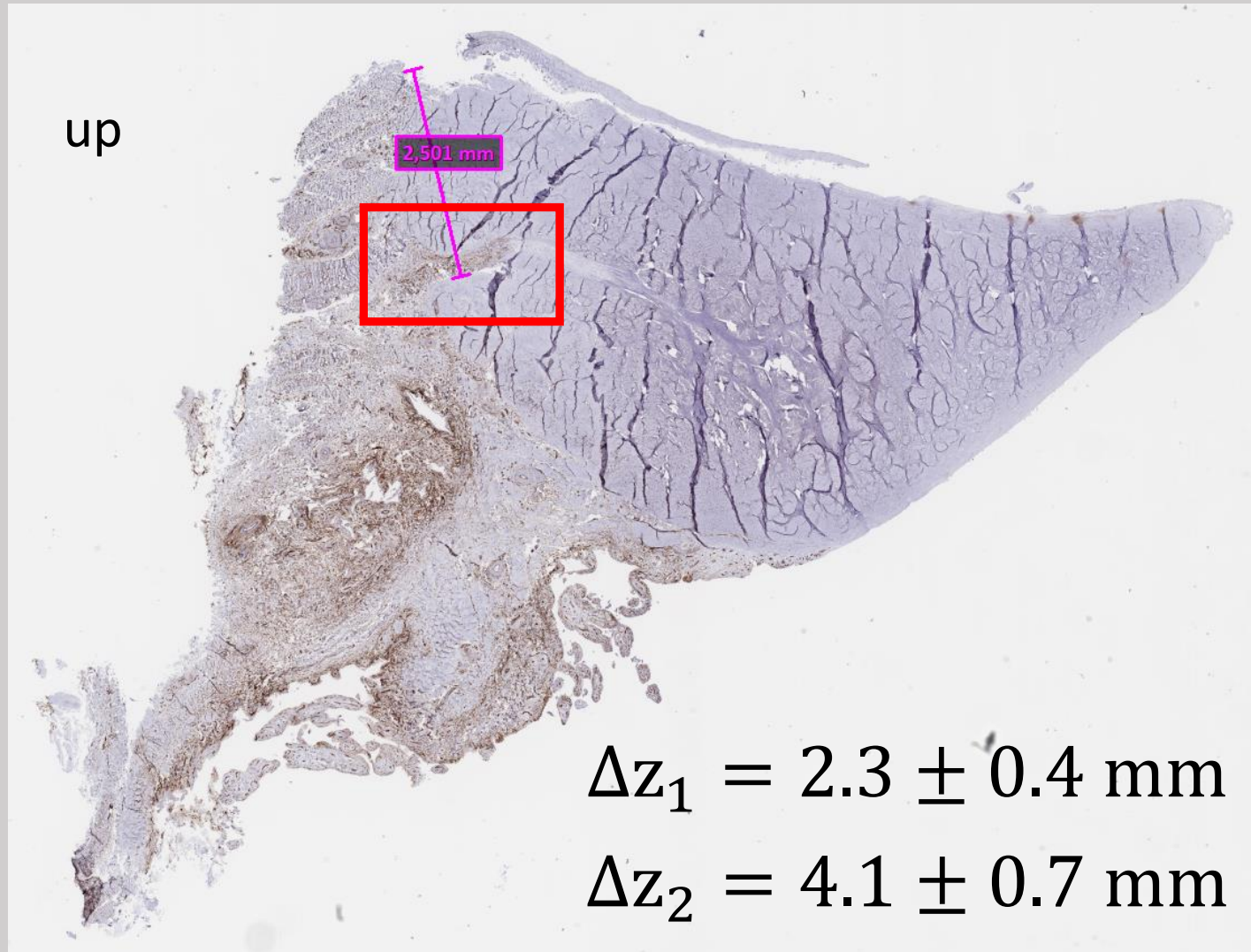


$$\Delta z_1 = 2.3 \pm 0.5 \text{ mm}$$

$$\Delta z_2 = 3.6 \pm 0.2 \text{ mm}$$

# Results and comparison


## Meniscus n° 6 - Histology






Conclusion

**First PA measurements show common points with  
histological slides and MRI**



**Auspicious results**



**Clinical study for proof-of-concept**

# Acknowledgements



**Phillipe Moreau  
Olivier Jacquin  
Eric Lacot  
Olivier Hugon**

**Cédric Lavet  
Béatrice Genoux  
Sylvie Sylvent**



**Hervé Mathieu**



**Régis Paillet**



**Alexandre Moreau-  
gaudry**



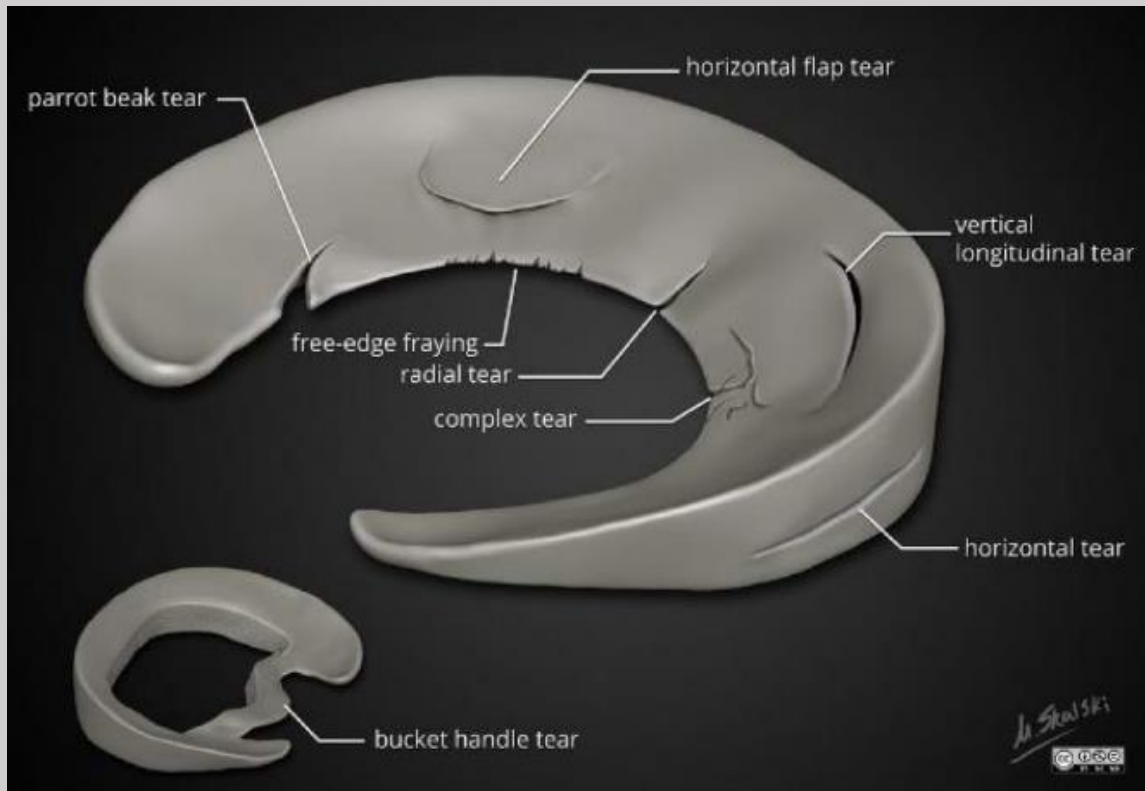
# References

- [1] Knee Anatomy, Zinovy Meyler, <https://www.arthritis-health.com/types/joint-anatomy/knee-anatomy> , 16/08/2022
- [2] Chirurgie orthopédique, <https://www.genouhanche.fr/fr/genou/arthrose/qu-est-ce-qu-une-prothese-totale-de-genou.html>, 16/08/2022
- [3] Pr Pierre Mansat, « Orthopédie Traumatologie », deuxième édition, Chapitre 15 – Item 357, page 269, Collège français des chirurgiens orthopédistes et traumatologues, Ellipses
- [4] Nitzan, M.; Nitzan, I.; Arieli, Y. The Various Oximetric Techniques Used for the Evaluation of Blood Oxygenation. *Sensors* **2020**, *20*, 4844. <https://doi.org/10.3390/s20174844>
- [5] 123RF, Vecteur genou humain vue latérale commune, [https://fr.123rf.com/photo\\_64645968\\_vecteur-genou-humain-vue-lat%C3%A9rale-commune.html?vti=nvhr4sj16buowdn9wn-1-22](https://fr.123rf.com/photo_64645968_vecteur-genou-humain-vue-lat%C3%A9rale-commune.html?vti=nvhr4sj16buowdn9wn-1-22), 22/08/2022

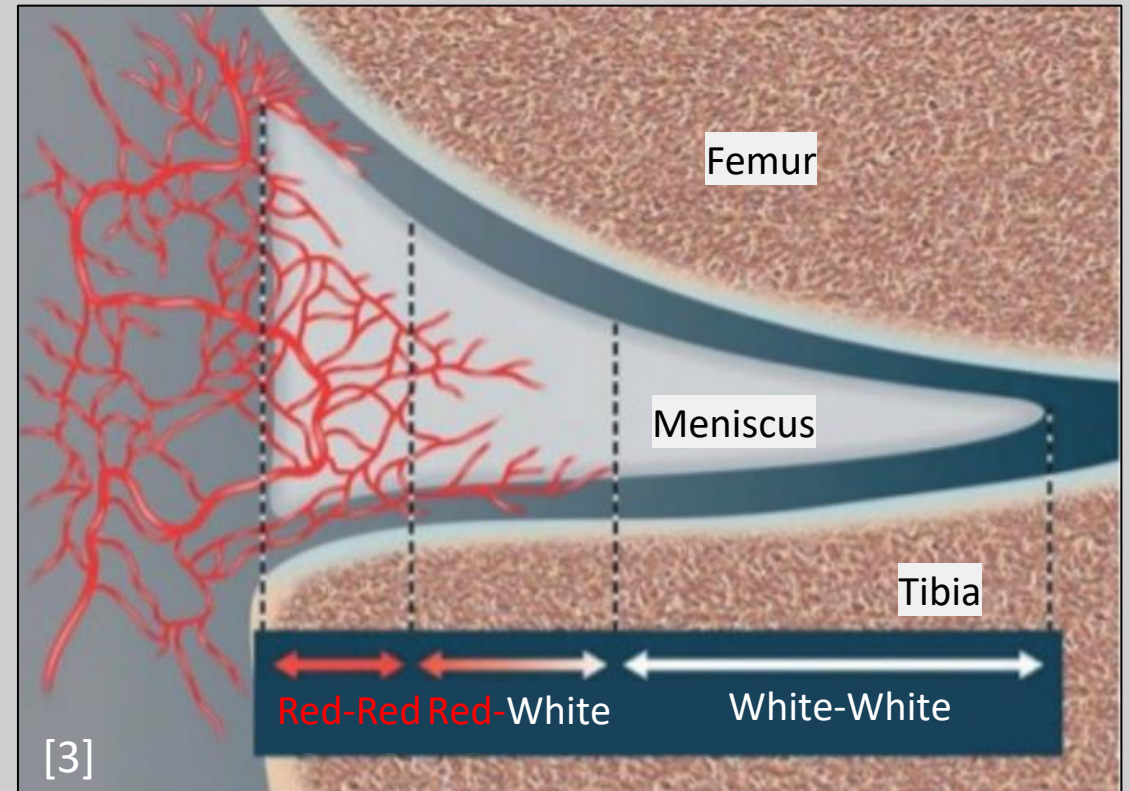
# The MénisCare project

## Meniscus suture or meniscectomy ?

### Tear pattern



### Tear location



# Photo acoustic imaging

## Conditions for photo acoustic effect



Absorption wavelength :

Blood

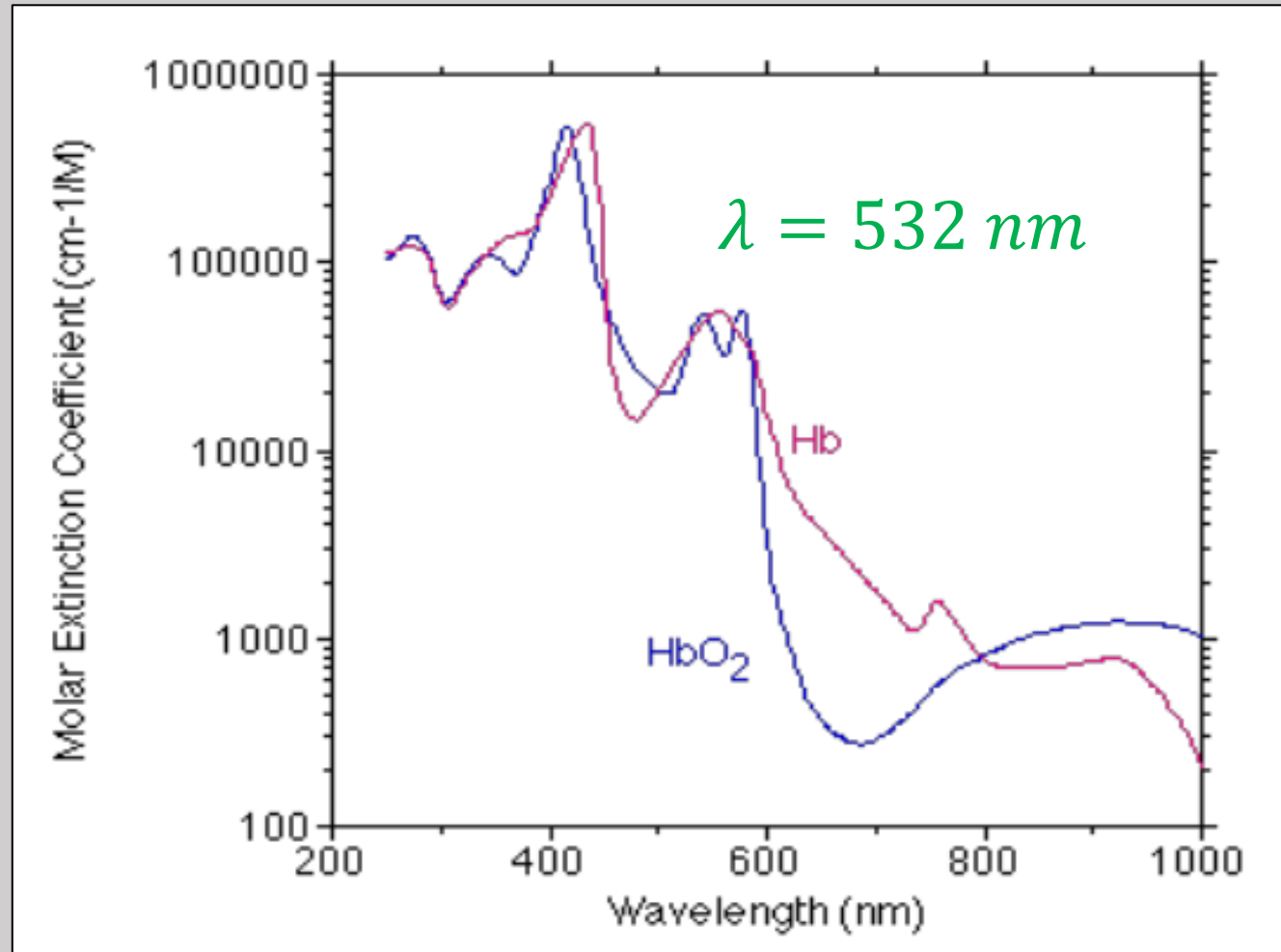


Figure 4 : Molar extinction coefficient of oxygenated (blue) and desoxygenated (pink) blood [4]

# Experimental set up Imaging the meniscus

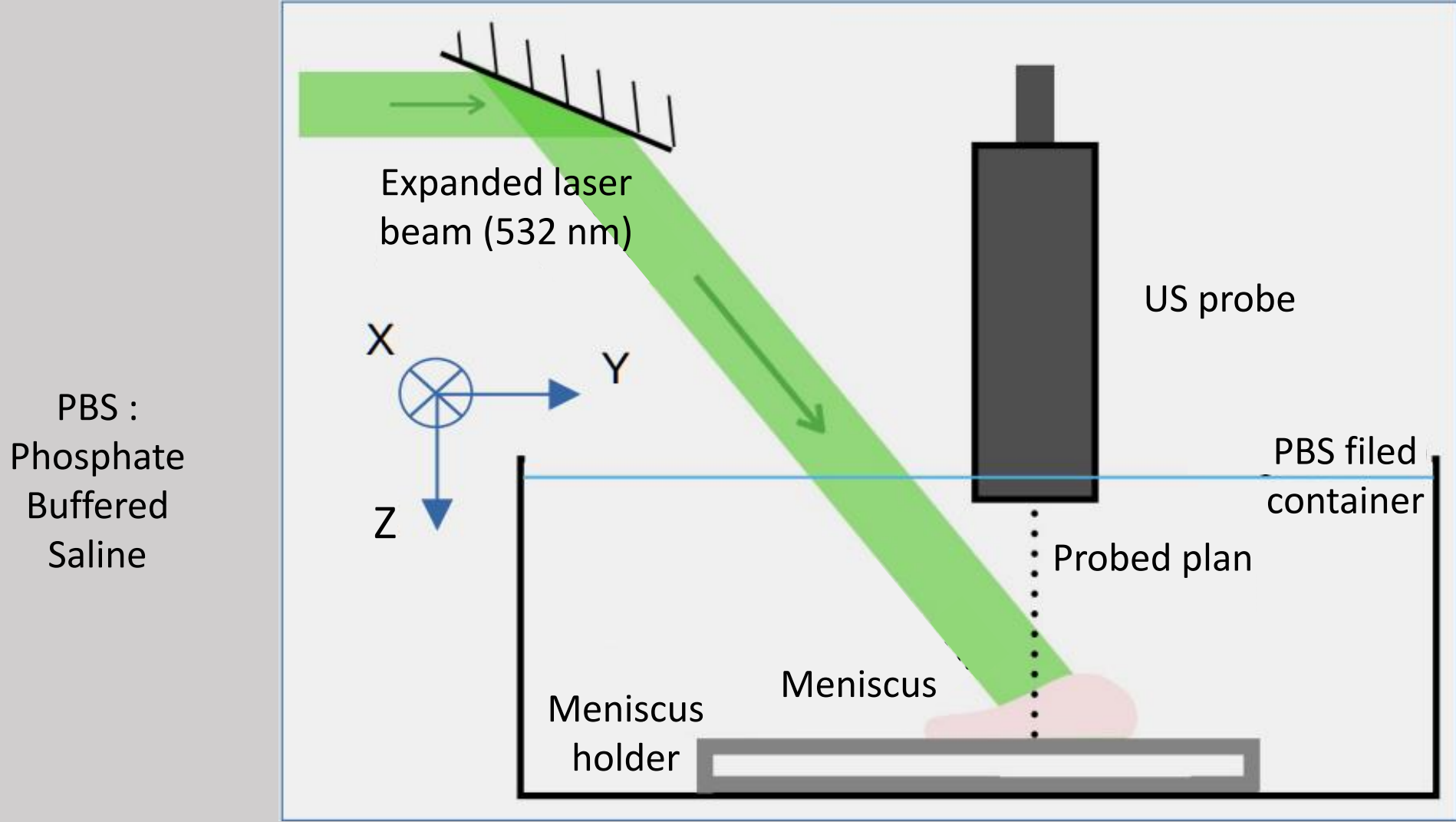


Figure 7 : Schematic diagram of the meniscus enlightenment.

# Experimental set up

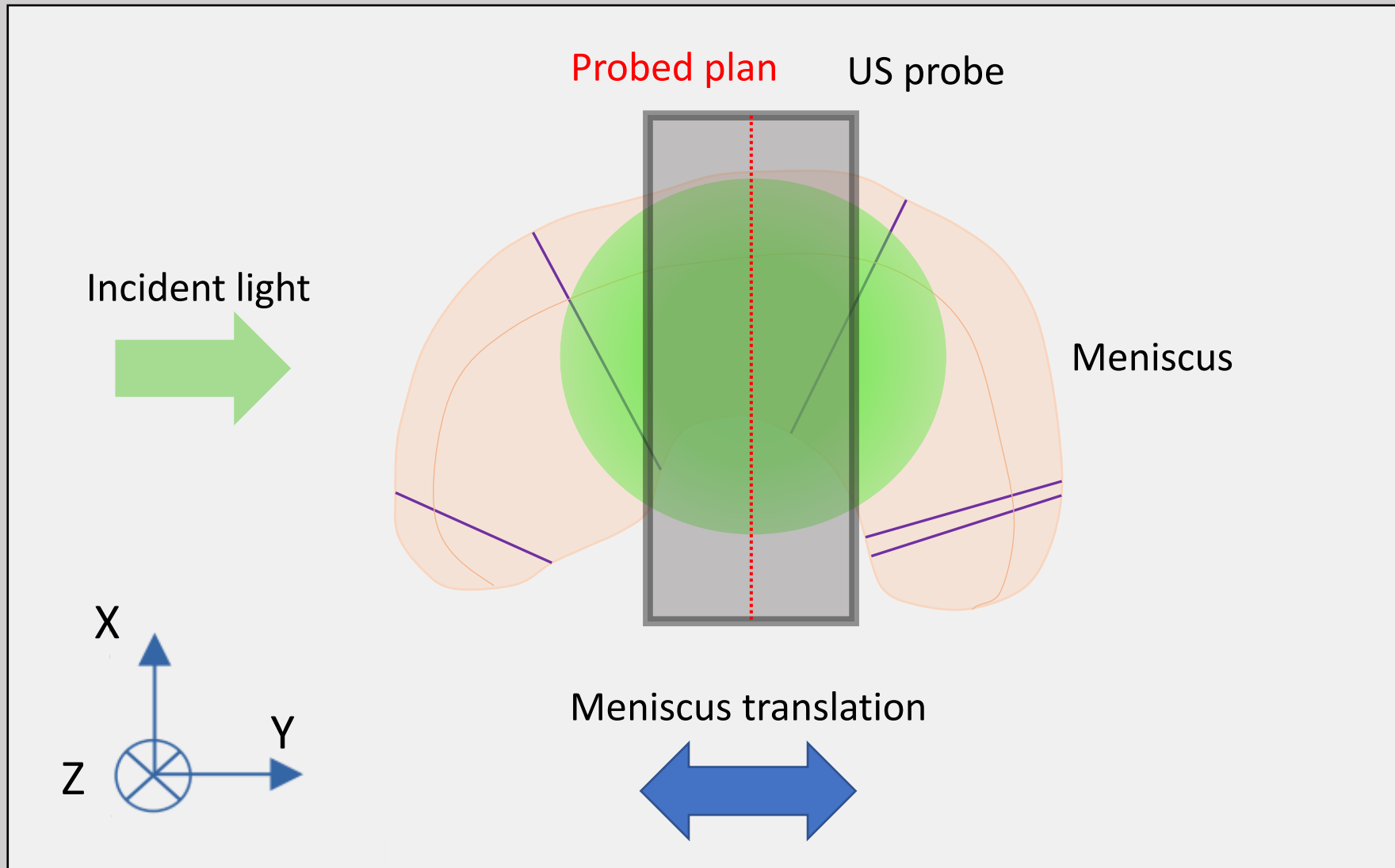





Figure 8 : Upper view of schematic diagram of meniscus enlightenment.

## Experimental set up



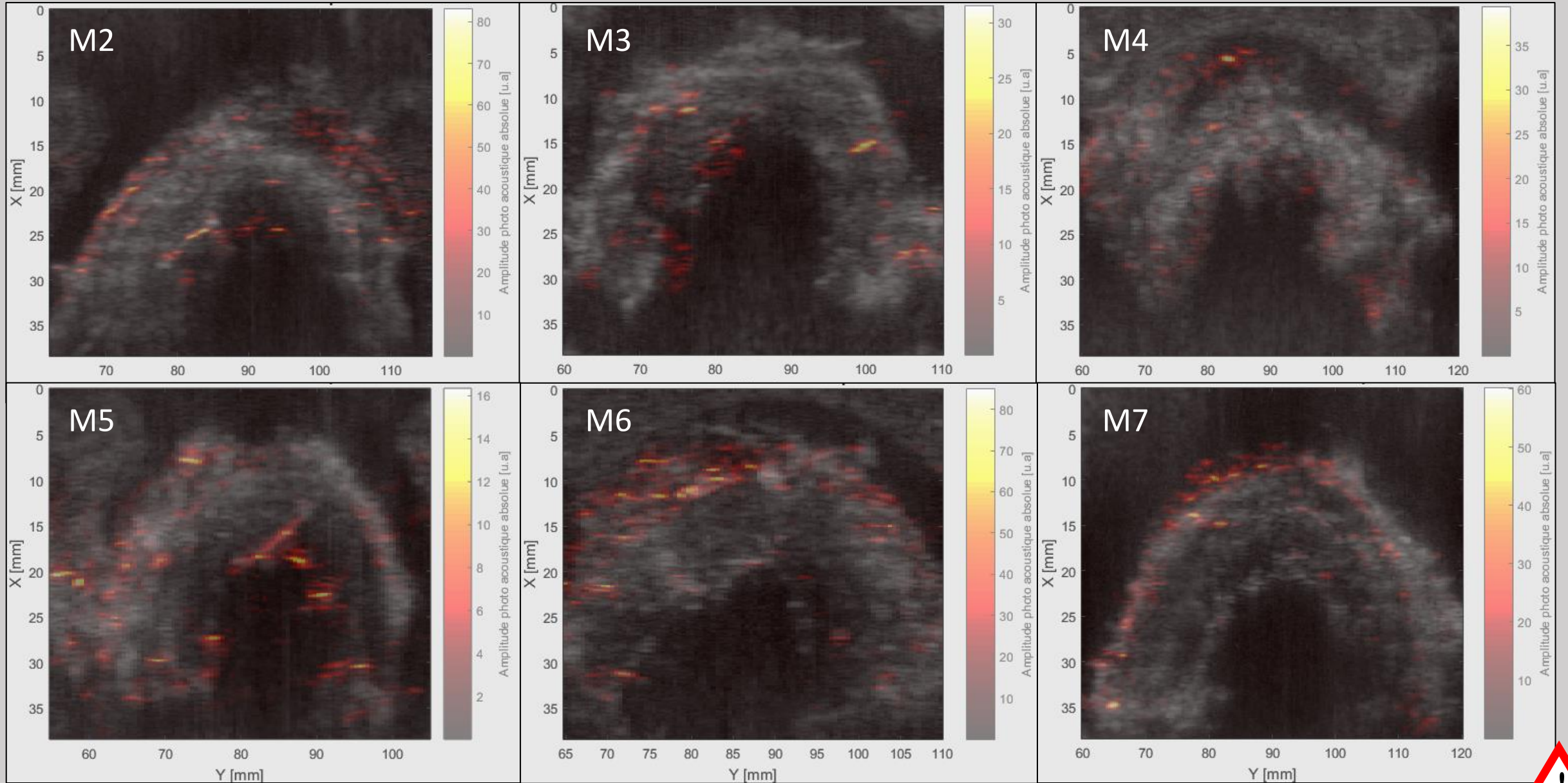
PBS container



PBS container with  
meniscus holder




# Results and comparison






# Results and comparison




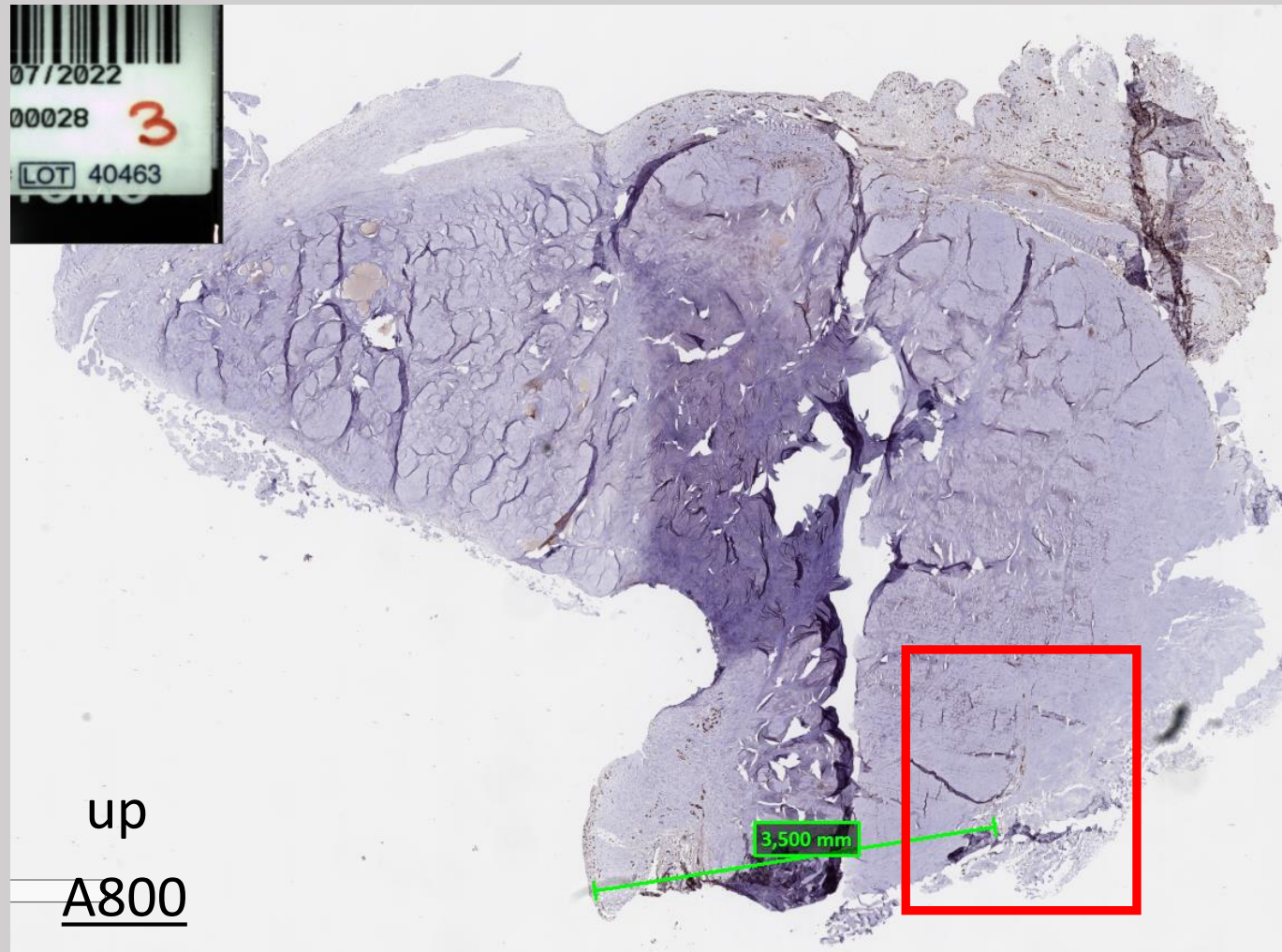
# Results and comparison Meniscus n° 6 - MRI





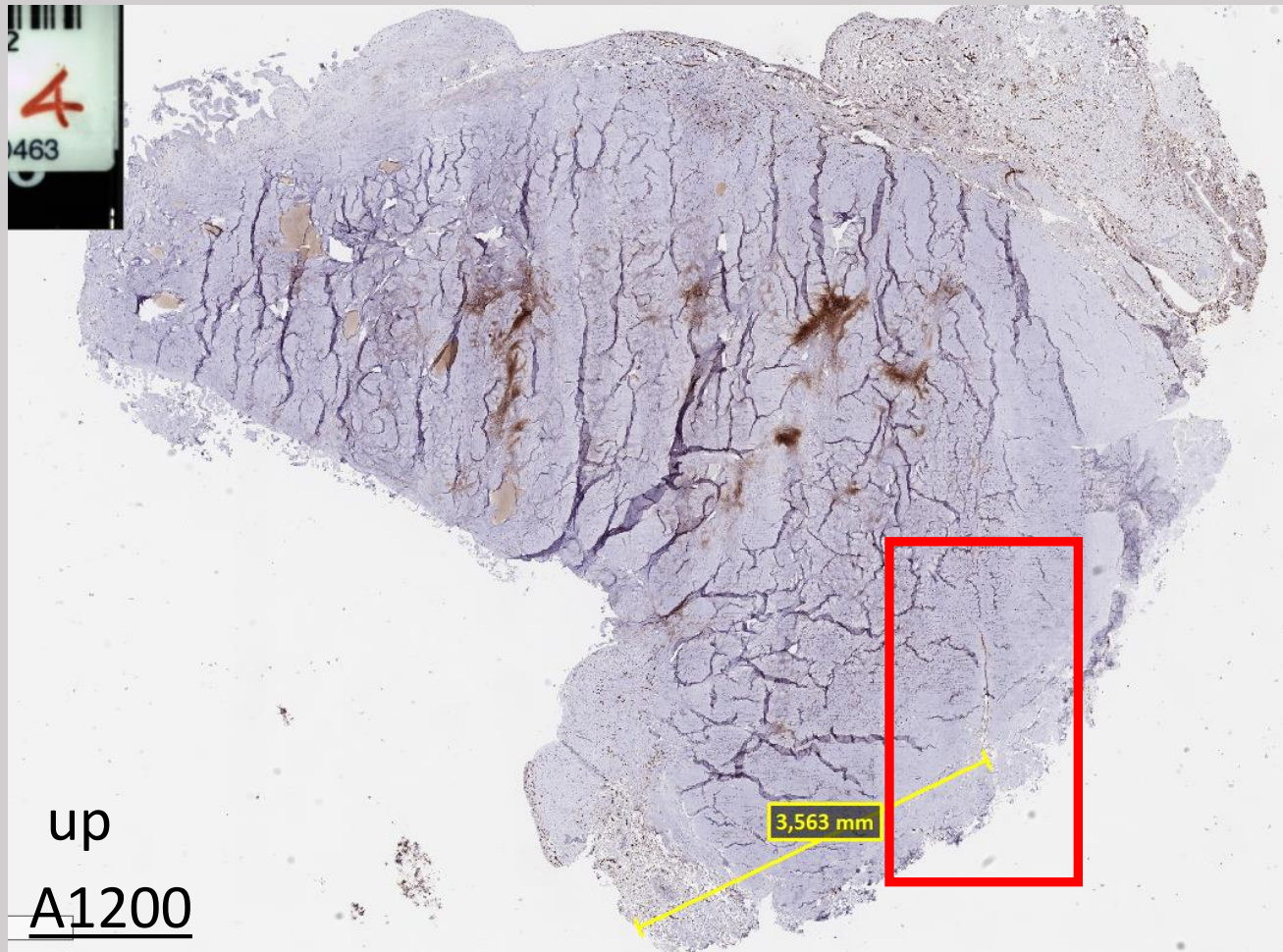
# Results and comparison

## Meniscus n° 4



# Results and comparison

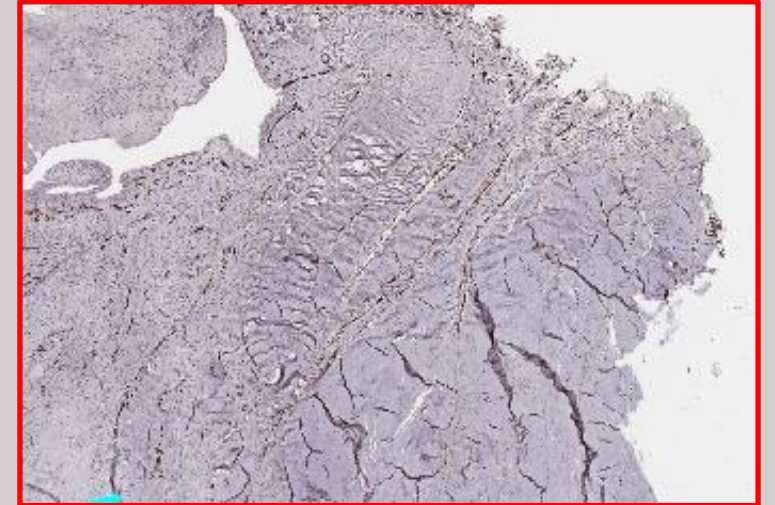
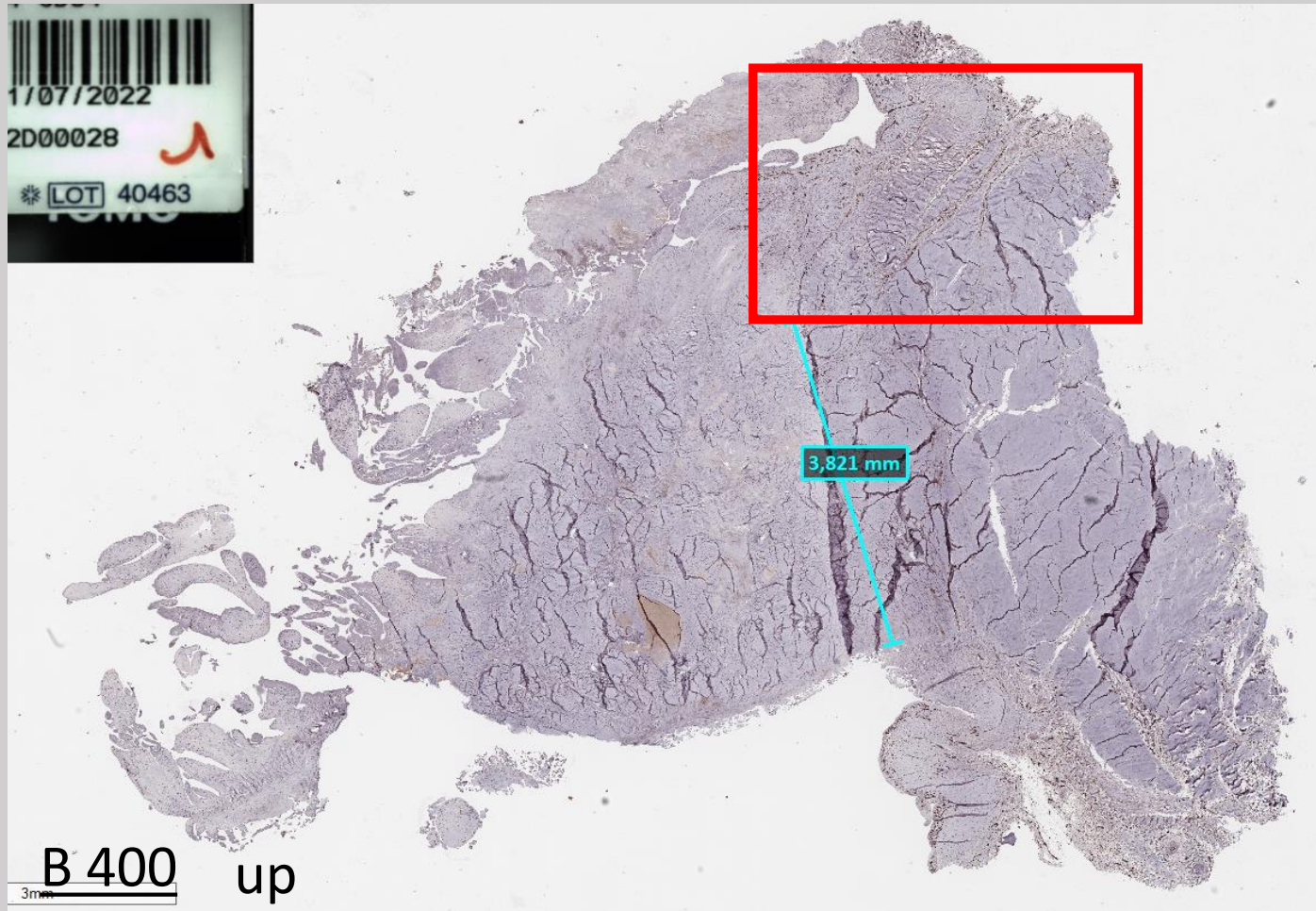
## Meniscus n° 4





# Results and comparison

## Meniscus n° 4



# Results and comparison

## Meniscus n° 4

